

CASE REPORT

Open Access



Porcine circovirus type 2 associated reproductive failure in a specific pathogen free (SPF) piglet producing herd in Norway: a case report

M. Oropeza-Moe^{1*} , A. J. Oropeza Delgado² and Tore Framstad³

Abstract

Background: Since 1999, scientists have published evidence of transplacental infection by porcine circovirus type 2 (PCV2) and reproductive failure in pigs. Affected herds have frequently been start-up herds, either naïve or with a high proportion of PCV2 susceptible gilts. Here, delayed farrowing in non-vaccinated gilts was observed in a commercial specific pathogen free (SPF) herd. Mummified fetuses and stillborn piglets recovered from these gilts were PCV2 positive.

Case presentation: The case herd was a self-recruiting, piglet producing unit of 240 sows. After detecting livestock associated methicillin resistant *Staphylococcus aureus* (LA-MRSA, CC398), stamping out was imposed by the authorities. An SPF herd was re-established and all dams were vaccinated against PCV2 until the farmer decided to exclude this vaccine. The first non-vaccinated batch consisted of 76% gilts. Here, one gilt showed signs of impending farrowing. This gilt was slaughtered three to four weeks after the expected farrowing date without having expelled any uterine contents. In the subsequent batch consisting of 79% gilts, three gilts showed similar clinical signs. Delayed farrowing was observed in two of these gilts and the uterine contents from the third gilt were recovered at the abattoir. Mummified fetuses and stillborn piglets were recovered from all three gilts. High levels of PCV2 DNA ($>10^7$ viral genomic copies/ 500 ng tissue) were found in myocardial samples by real-time PCR analysis. One myocardial sample submitted for immunohistochemical (IHC) analysis showed moderate amounts of PCV2 antigen. In the subsequent batch consisting of 77% gilts, several weak-born piglets were seen across different litters.

Conclusions: This case report describes an apparent link between in utero PCV2 infection, pre partum nest-building behaviour, mammary development and delayed farrowing. To date, no reports have described imminent signs of farrowing and delayed farrowing as clinical signs in conjunction with transplacental PCV2 infection in Norway. Reinitiation of PCV2 vaccination was strongly advised in this herd due to recent depopulation and repopulation and the high proportion of gilts. Vaccination was effective because no further cases have occurred since.

Keywords: Gilt, PCV2, Delayed farrowing, Mammary development, Mammary involution, Reproductive failure

Background

Circoviruses are host specific viruses [1]. *Porcine circovirus type 1* (PCV1) and *porcine circovirus type 2* (PCV2) are acknowledged as the non-pathogenic and pathogenic types in swine, respectively [2]. PCV2 has been associated with a number of conditions collectively known as porcine

circovirus diseases (PCVD). PCV2 has been suggested to play a role in the so-called porcine respiratory disease complex (PRDC), enteritis, porcine dermatitis and nephropathy syndrome (PDNS) and proliferative and necrotizing pneumonia (PNP) [3, 4]. A Canadian report published in 1999 was the first to describe PCV2 involvement in reproductive failure in swine [5]. Since then, several reports have documented PCV2-associated reproductive failure [6–19]. Affected herds have frequently been start-up herds in which the number of susceptible gilts is

* Correspondence: marianne.oropeza-moe@nmbu.no

¹Norwegian University of Life Sciences (NMBU), Faculty of Veterinary Medicine, Department of Production Animal Clinical Sciences, Campus Sandnes, Sandnes, Norway

Full list of author information is available at the end of the article

high or PCV2 seronegative herds [3, 5, 20]. Typical clinical signs associated with PCV2-associated reproductive failure are mummified, stillborn and weak-born piglets along with the macroscopical pathological findings including cardiomyopathy, pulmonary edema, hepatomegaly, and ascites [5, 8]. The most consistent microscopic changes include myocardial degeneration, fibrosis, and nonsuppurative to necrotizing or fibrosing myocarditis [5, 8, 21]. These changes are due to an apparent PCV2 tropism for fetal myocardiocytes, which diminishes with gestational age [22]. In the later stages of gestation, increased levels of PCV2 can be detected in lymphoid organs [21]. Clinical history, necropsy findings, histopathological and viral examination of fetal tissue samples demonstrating characteristic lesions and presence of PCV2 are necessary for the confirmative diagnosis of PCV2-associated reproductive failure.

Numerous laboratories have established methods for PCV2 DNA or antigen detection, e.g. real-time PCR or immunohistochemical (IHC) analyses. Clinical presentation of abortion, mummified fetuses and stillbirths in swine must be distinguished from other diseases caused by *porcine reproductive and respiratory syndrome virus* (PRRSV), *porcine parvovirus* (PPV), *pseudorabies virus*, *porcine enterovirus* (PEV) and *encephalomyelitis virus* (EMCV) [2, 23].

Vaccines against PCV2 infection are quite effective [24, 25] and vaccines marketed for sows exist (Circovac[®], Merial, Lyon, France; Ingelvac CircoFLEX[®], Boehringer Ingelheim Vetmedica GmbH, Ingelheim/ Rhein, Germany). The elected timepoint of dam vaccination can influence the antibody levels in piglets [26].

Information regarding transplacental PCV2 infection in conjunction with imminent signs of parturition (nest-building activity and mammary development) or delayed farrowing in gilts is limited [5, 27].

The aim of this case report is to describe the apparent correlation between transplacental PCV2 infection, mammary development and nest-building activity prior to the expected farrowing date and subsequently mammary involution and delayed farrowing (> 118 days) in a Norwegian commercial piglet producing SPF herd.

Case presentation

The case herd was a self-recruiting, commercial piglet producing herd of 240 sows.

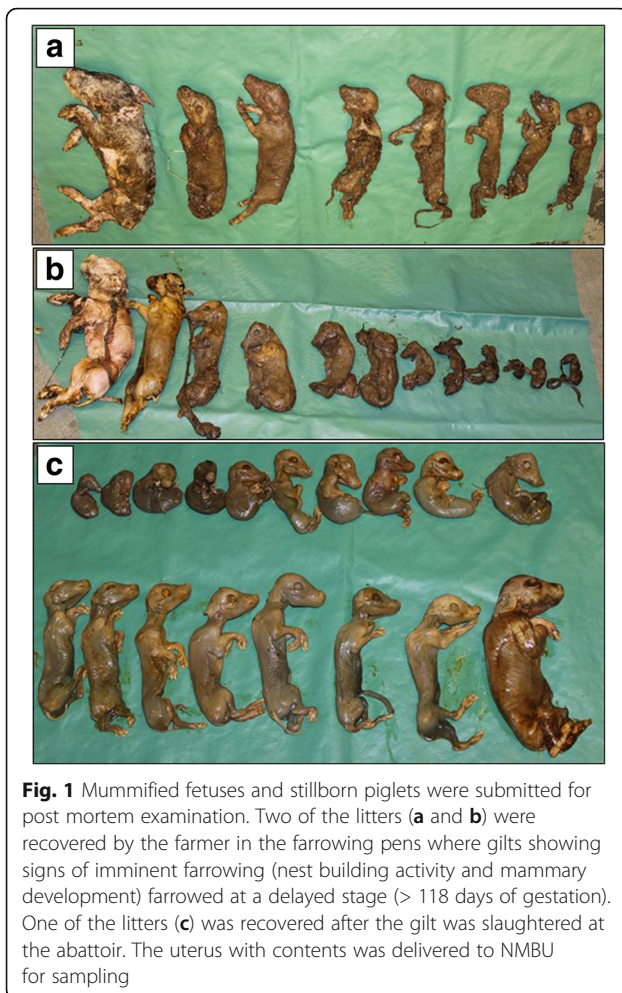
It was diagnosed with livestock associated methicillin resistant *Staphylococcus aureus* (LA-MRSA, C398) in April 2014. Norway has a national strategy for LA-MRSA including a search-and-destroy policy [28]. Therefore, the farmer was imposed stamping out the entire herd of 2550 pigs. The farm was decontaminated during the autumn of 2014 and the farmer decided to reestablish a closed SPF breeding herd. Landrace x Yorkshire gilts (210 days of age) were bought from one SPF breeding unit (free of

Actinobacillus pleuropneumoniae, *Pasturella multocida*, *Mycoplasma hyopneumoniae*, *Brachyspira hyodysenteriae* and *Brachyspira pilosicoli*) until late autumn 2015. The farmer conducted insemination with Landrace semen (Norsvin SA, Hamar, Norway) and applied transabdominal ultrasound for determination of pregnancy. The herd had 1 gestation unit, 3 farrowing units and 3 weaner units. In the gestation unit, gilts and sows were kept in separate pens. The gestation unit was not washed and disinfected regularly. The farrowing units were washed and disinfected between every two to three batches. Every 7 weeks, around 70 sows farrowed.

Sows and gilts were fed standard gestation (Avlsfôr, Fiskå Mølle, Norway) and lactation diets (Opti Lakta, Fiskå Mølle, Norway). The gilts and sows were vaccinated against *Escherichia coli* (Neocolipor[®], Merial Norden A/S, Denmark), PCV2 (Circovac[®], Merial Norden A/S, Denmark), *Porcine parvovirus and Erysipelothrix rhusiopathiae* (Parvoruvax[®], Merial Norden A/S, Denmark) according to the manufacturers recommendations. The farmer ceased to vaccinate dams against PCV2 in October 2015 since no beneficial effects on the overall production were perceived.

In the first non-vaccinated batch consisting of 17 sows and 53 gilts (76% gilts), one gilt showed nest-building activity and mammary development without farrowing when expected. The gilt was slaughtered between three and four weeks after the expected farrowing date. The uterine contents were not examined. In the subsequent batch consisting of 15 sows and 55 gilts (79% gilts), three gilts showed similar clinical signs. Mummified fetuses and stillborn piglets (Litter A and B, Fig. 1a and b) were found in the pens approximately 20 and 24 days after the expected farrowing dates, respectively. Post mortem examination was conducted at the Norwegian University of Life Sciences (Sandnes, Norway). The weight/ crown-rump length (CRL) varied from 152 g/ 16 cm to 1380 g/ 29 cm in Litter A and from 31 g/ 9 cm to 1455 g/ 30 cm in Litter B. At the abattoir, 18 mummified fetuses were recovered from the remaining gilt (Litter C, Fig. 1c) sent to the abattoir 25 days after the expected farrowing date. Here, the weight/ CRL varied from 26 g/ 7 cm to 551 g/ 22 cm. In the subsequent batch consisting of 16 sows and 55 gilts (77% gilts), the number of weak born piglets across several gilt litters was high, but no exact numbers of weak born piglets across different litters were documented. However, 19 out of 20 piglets in one particular litter died within the first 24 h after birth. Unfortunately none of these weak born piglets were submitted for post mortem examinations. Udder involution was observed in all affected gilts around one week after the expected farrowing date.

Myocardial samples from two stillborn piglets representing Litter A and B were considered suitable for both



histopathological and IHC analyses whereas the myocardium of the remaining mummified fetuses showed signs of advanced autolysis. The samples were processed by the DTU National Veterinary Institute (Copenhagen, Denmark). The myocardial samples from one piglet (Litter B) showed focal, subendocardial infiltrations of mononuclear cells (Fig. 2) and PCV2 capsid antigen was detected within myocytes with a non-commercial (F217) monoclonal antibody.

Bacteriological examinations of thoracic and abdominal organs (sheep blood agar, 37 °C, 5% CO₂, 48 h) from all mummified and stillborn fetuses were negative.

High levels of PCV2 DNA (>10⁷ viral genomic copies/500 ng tissue) were detected by real-time PCR in nine myocardial samples from three piglets from litters A, B and C, respectively. Real-time PCR was conducted by the DTU National Veterinary Institute (Copenhagen, Denmark). No *Porcine teschovirus* (PTV) was detected in pulmonary samples from the three litters by real-time PCR [29]. This analysis was performed by the Instituto Nacional de Investigación y Tecnología Agraria y Alimentaria (INIA, Madrid, Spain). Real-time PCR analyses for *Porcine Parvovirus* (PPV)

and *Porcine Reproductive and Respiratory Syndrome Virus* (PRRSV) on pooled liver samples (five from each litter) and pleural fluid from one piglet per litter, respectively, were negative (DTU National Veterinary Institute, Copenhagen, Denmark).

Serum samples from three randomly selected gilts and sows in the affected batch consisting of 79% gilts were analysed serologically. Antibody levels against *Leptospira icterohemorrhagiae*, *Chlamydia abortus*, EMCV or PEV were negative.

Based on the clinical signs, post mortem examinations and real-time PCR results, the farmer was advised to reinitiate vaccination against PCV2. All dams have been vaccinated with Circovac[®] since, and no similar cases have occurred.

Discussion

There was an apparent correlation between PCV2 associated reproductive failure in non-vaccinated gilts and clinical signs of imminent parturition (mammary development and nest building activity), as well as mammary involution and delayed farrowing in the case herd. Two of the affected gilts expelled their PCV2 positive uterine contents three and four weeks after expected farrowing date. Additionally, two affected gilts were sent to the abattoir without having expelled the uterine contents. Mummified fetuses were recovered from one of these gilts and the fetuses were confirmed PCV2 positive. To the Authors knowledge, the correlation between trans-placental PCV2 infection and the abovementioned clinical signs has been described twice previously [5, 27]. No reports from Norway have been published, describing this apparent link.

The criteria for diagnosis of PCV2 associated reproductive failure proposed by Segalés et al. were fulfilled in the case herd, including: (1) clinical signs which can include increased numbers of mummified fetuses, stillborns or weak-born pigs, (2) microscopic lesions within fetal tissues (heart or lymphoid tissues) and (3) PCV2 antigen or DNA within fetal tissues [4].

Dams carrying mummies and/ or stillborn piglets may farrow prematurely, at the expected time or later than expected time of farrowing [30]. If all fetuses die, the return to normal ovarian cyclicity may fail due to persistent corpora lutea [31]. If infection occurs during late gestation (70–115 days of gestation), the hormonal influence on pregnancy may remain and typical signs of impending parturition, like mammary development, may appear. All affected gilts in the case herd showed mammary development close to the expected farrowing time. Mammary involution occurred around one week after the expected farrowing time, a simple consequence of unsuckled mammary glands [32].

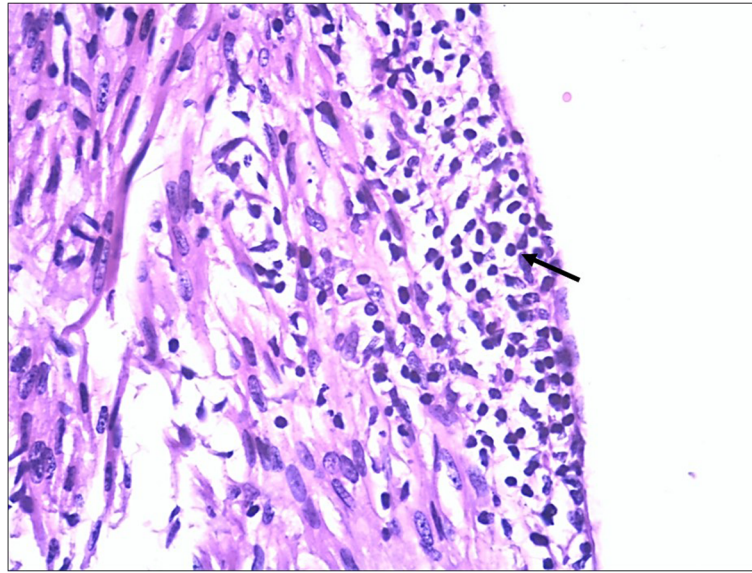


Fig. 2 Myocardial inflammatory changes characterized by infiltrating mononuclear cells (arrows). Hematoxylin and eosin (HE) (magnification $\times 40$)

Microscopic myocardial lesions including infiltration of mononuclear cells were found along with PCV2 antigen identified by IHC. However, only one of two submitted samples could identify PCV2 by IHC. Fetal gross lesions are not always present following in utero PCV2 infection [33, 34]. Therefore, it may be challenging to select a representative sample for IHC staining. In the submitted samples, the cellular morphology of the labelled cells was often disrupted due to autolysis of the tissue. In this case, the detection of high levels of PCV2 DNA ($>10^7$ viral genomic copies/ 500 ng tissue) by real-time PCR in fetal samples was essential for etiology determination.

The actual route of transmission remains unknown. Unfortunately none of the numerous weak-born piglets born in the third affected batch were submitted for post mortem examination. Based on previous reports, there is reason to believe that the clinical signs displayed by these piglets could very well be due to PCV2 infection [5, 6, 8, 35–37].

No further cases occurred after reinitiating vaccination against PCV2. Our assumption is that the unvaccinated gilts were PCV2 naïve and infected during pregnancy. The different sizes of mummified fetuses indicate PCV2 infection of the affected gilts between 40 and 70 days of pregnancy [13, 38].

Serological testing for *Leptospira icterohaemorrhagica*, *Chlamydia abortus*, EMCV and *Porcine enterovirus group 1* antibodies was negative. Possible co-infections with other reproductive failure associated pathogens seem highly unlikely since all dams remained healthy until gilts started showing signs of reproductive failure.

The reintroduction of vaccination with Circovac® was effective since no further cases have occurred in the

herd. Although PCV2 associated reproductive failure has been reported in PCV2 seropositive dams [39] and PCV2 vertical transmission has been shown to occur in PCV2-vaccinated dams [34], the correct timing of vaccination of sows and gilts can reduce viremia in the dam.

Conclusions

This is the first case report to describe an apparent association between transplacental PCV2 infection in commercial SPF gilts and imminent signs of farrowing as well as delayed farrowing in Norway. PCV2 was confirmed in fetuses from three litters showing macroscopic and microscopic findings compatible with an in utero PCV2 infection. No further cases have occurred since reinitiating vaccination against PCV2, indicating a protective effect on PCV2 associated reproductive failure in the case herd.

Abbreviations

DTU: National Veterinary Institute; EMCV: *encephalomyelitis virus*; IHC: Immunohistochemical; livestock associated methicillin resistant *Staphylococcus aureus*; INIA: Instituto Nacional de Investigación y Tecnología Agraria y Alimentaria; LA-MRSA: Livestock-associated methicillin resistant *Staphylococcus aureus*; NMBU: Norwegian University of Life Sciences; PCR: Polymerase chain reaction; PCV1: *Porcine circovirus type 1*; PCV2: *Porcine circovirus type 2*; PCVD: Porcine circovirus diseases; PEV: *Porcine enterovirus*; PPV: *Porcine parvovirus*; PRRSV: *Porcine reproductive and respiratory syndrome virus*; PTV: *Porcine teschovirus*; SPF: Specific pathogen-free

Acknowledgements

The Authors wish to acknowledge the farmer allowing the results from this case report to be published.

Funding

Not applicable.

Availability of data and materials

The data generated during the current case report are kept and stored by the corresponding author. The data are available from the corresponding author on reasonable request.

Authors' contributions

MOM drafted the manuscript. AO performed the herd visits. MOM carried out necropsies and sample isolation. TF supervised this case report and helped to draft the manuscript. All authors read and approved the final manuscript.

Ethics approval

No ethics approval was necessary since this case report describes routine procedures conducted by the involved veterinarian practitioners during the search for the cause of reproductive failure in the gilts in the case herd. The farmer gave his consent to participate.

Consent for publication

The farmer gave his consent to publish the results from the analyses of samples originating from his gilts.

Competing interests

The authors declare that they have no competing interests.

Publisher's Note

Springer Nature remains neutral with regard to jurisdictional claims in published maps and institutional affiliations.

Author details

¹Norwegian University of Life Sciences (NMBU), Faculty of Veterinary Medicine, Department of Production Animal Clinical Sciences, Campus Sandnes, Sandnes, Norway. ²Fiskå Mølle AS, Tau, Norway. ³Norwegian University of Life Sciences (NMBU), Faculty of Veterinary Medicine, Department of Production Animal Clinical Sciences, Campus Adamstuen, Oslo, Norway.

Received: 6 July 2017 Accepted: 5 October 2017

Published online: 24 October 2017

References

- Gillespie J, Opriessnig T, Meng XJ, Pelzer K, Buechner-Maxwell V. Porcine circovirus type 2 and porcine circovirus-associated disease. *J Vet Intern Med.* 2009;23:1151–63.
- Madson DM, Opriessnig T. Effect of porcine circovirus type 2 (PCV2) infection on reproduction: disease, vertical transmission, diagnostics and vaccination. *Anim Health Res Rev.* 2011;12:47–65.
- Opriessnig T, Meng X-J, Halbur PG. Porcine circovirus type 2 associated disease: update on current terminology, clinical manifestations, pathogenesis, diagnosis, and intervention strategies. *J Vet Diagn Investig Off Publ Am Assoc Vet Lab Diagn Inc.* 2007;19:591–615.
- Segalés J, Allan GM, Domingo M. Porcine circovirus diseases. *Anim Health Res Rev.* 2005;6:119–42.
- West KH, Bystrom JM, Wojnarowicz C, Shantz N, Jacobson M, Allan GM, et al. Myocarditis and abortion associated with intrauterine infection of sows with porcine circovirus 2. *J Vet Diagn Investig Off Publ Am Assoc Vet Lab Diagn Inc.* 1999;11:530–2.
- Madson DM, Patterson AR, Ramamoorthy S, Pal N, Meng XJ, Opriessnig T. Reproductive failure experimentally induced in sows via artificial insemination with semen spiked with porcine circovirus type 2. *Vet Pathol.* 2009;46:707–16.
- Mateusen B, Maes DGD, Van Soom A, Lefebvre D, Nauwynck HJ. Effect of a porcine circovirus type 2 infection on embryos during early pregnancy. *Theriogenology.* 2007;68:896–901.
- O'Connor B, Gauvreau H, West K, Bogdan J, Ayroud M, Clark EG, et al. Multiple porcine circovirus 2-associated abortions and reproductive failure in a multisite swine production unit. *Can Vet J.* 2001;42:551–3.
- Allan GM, McNeilly F, Cassidy JP, Reilly GAC, Adair B, Ellis WA, et al. Pathogenesis of porcine circovirus; experimental infections of colostrum deprived piglets and examination of pig foetal material. *Vet Microbiol.* 1995; 44:49–64.
- Pittman JS. Reproductive failure associated with porcine circovirus type 2 in gilts. *J Swine Health Prod.* 2008;16:144–8.
- Johnson CS, Joo HS, Direksin K, Yoon K-J, Choi YK. Experimental in utero inoculation of late-term swine fetuses with porcine circovirus type 2. *J Vet Diagn Investig Off Publ Am Assoc Vet Lab Diagn Inc.* 2002;14:507–12.
- Mateusen B, Sanchez RE, Soom AV, Meerts P, Maes DGD, Nauwynck HJ. Susceptibility of pig embryos to porcine circovirus type 2 infection. *Theriogenology.* 2004;61:91–101.
- Pensaert MB, Sanchez RE Jr, Ladekjær-Mikkelsen A-S, Allan GM, Nauwynck HJ. Viremia and effect of fetal infection with porcine viruses with special reference to porcine circovirus 2 infection. *Vet Microbiol.* 2004;98:175–83.
- Sanchez RE, Meerts P, Nauwynck HJ, Ellis JA, Pensaert MB. Characteristics of porcine circovirus-2 replication in lymphoid organs of pigs inoculated in late gestation or postnatally and possible relation to clinical and pathological outcome of infection. *J Vet Diagn Investig Off Publ Am Assoc Vet Lab Diagn Inc.* 2004;16:175–85.
- Josephson G, Charbonneau G. Case report of reproductive problem in a new startup operation. *J Swine Health Prod.* 2001;9:258–9.
- Segalés J. Porcine circovirus type 2 (PCV2) infections: clinical signs, pathology and laboratory diagnosis. *Virus Res.* 2012;164:10–9.
- Brunborg IM, Jonassen CM, Moldal T, Bratberg B, Lium B, Koenen F, et al. Association of Myocarditis with high viral load of porcine Circovirus type 2 in several tissues in cases of fetal death and high mortality in piglets. A case study. *J Vet Diagn Investig.* 2007;19:368–75.
- Karlsen OM, Kolbjørnsen Ø, Framstad T. Saminfeksjon av Porcint circovirus type 2 (PCV2) og Porcint parvovirus (PPV) i en norsk formeringsbesetning. In: *Husdyrforsøksmøteboken 2013.* Norway: Thon Hotel Arena, Lillestrøm; 2013. p. 179–81.
- Yoon K-J, Jepsen RJ, Pogranichniy RM, Sorden S, Stammer R, Evans LE. A novel approach to intrauterine viral inoculation of swine using PCV type 2 as a model. *Theriogenology.* 2004;61:1025–37.
- Togashi K, Mawatari T, Mitobe S, Moriya S. Reproductive losses associated with porcine circovirus type 2 in a Japanese herd of seronegative sows. *J Vet Med Sci.* 2011;73:941–4.
- Sanchez RE, Meerts P, Nauwynck HJ, Pensaert MB. Change of porcine circovirus 2 target cells in pigs during development from fetal to early postnatal life. *Vet Microbiol.* 2003;95:15–25.
- Sanchez RE, Nauwynck HJ, McNeilly F, Allan GM, Pensaert MB. Porcine circovirus 2 infection in swine foetuses inoculated at different stages of gestation. *Vet Microbiol.* 2001;83:169–76.
- Ramirez A. Differential diagnosis of diseases. In: *Diseases of swine.* 10th ed. West Sussex, UK: Wiley-Blackwell; 2012. p. 18–31.
- Opriessnig T, Madson DM, Prickett JR, Kuhar D, Lunney JK, Elsenner J, et al. Effect of porcine circovirus type 2 (PCV2) vaccination on porcine reproductive and respiratory syndrome virus (PRRSV) and PCV2 coinfection. *Vet Microbiol.* 2008;131:103–14.
- Seo HW, Park C, Han K, Chae C. Effect of porcine circovirus type 2 (PCV2) vaccination on PCV2-viremic piglets after experimental PCV2 challenge. *Vet Res.* 2014;45:13.
- López-Soria S, Sibila M, Pleguezuelos P, Cuadrado R, López-Jiménez R, Pérez D, et al. Sow vaccination against porcine circovirus type 2 at different physiological stages: effects on reproductive parameters and passive immunity in piglets. In: *Proceedings ESPHM 2017.* Prague: Czeck Republik; 2017. p. 99.
- Ladekjær-Mikkelsen AS, Nielsen J, Storgaard T, Bøtner A, Allan G, McNeilly F. Transplacental infection with PCV-2 associated with reproductive failure in a gilt. *Vet Rec.* 2001;148:759–60.
- Grøntvedt CA, Elstrøm P, Stegger M, Skov RL, Skytt Andersen P, Larssen KW, et al. Methicillin-resistant *Staphylococcus Aureus* CC398 in humans and pigs in Norway: a "one health" perspective on introduction and transmission. *Clin Infect Dis.* 2016;63:1431–8.
- Cano-Gómez C, Buitrago D, Fernández-Pinero J, Fernández-Pacheco P, Mansilla C, Agüero M, et al. Evaluation of a fluorogenic real-time reverse transcription-polymerase chain reaction method for the specific detection of all known serotypes of porcine teschoviruses. *J Virol Methods.* 2011;176:131–4.
- Vanderhaeghe C. Incidence and prevention of early parturition and risk factors for stillborn piglets. Doctoral degree. Ghent University; 2010. http://www.rohh.ugent.be/v3/research/phd/2010/Vanderhaeghe_C.pdf.
- Almond GW, Flowers WL, Batista L, D'Allaire S. Diseases of the Reproductive System. In: *Diseases of Swine.* 9th ed. Ames, Iowa, USA: Wiley-Blackwell; 2006. p. 113–48.

32. Farmer C. Review: mammary development in swine: effects of hormonal status, nutrition and management. *Can J Anim Sci.* 2012;93:1–7.
33. Madson DM, Patterson AR, Ramamoorthy S, Pal N, Meng XJ, Opriessnig T. Effect of natural or vaccine-induced porcine circovirus type 2 (PCV2) immunity on fetal infection after artificial insemination with PCV2 spiked semen. *Theriogenology.* 2009;72:747–54.
34. Madson DM, Patterson AR, Ramamoorthy S, Pal N, Meng XJ, Opriessnig T. Effect of porcine Circovirus type 2 (PCV2) vaccination of the dam on PCV2 replication in Utero. *Clin Vaccine Immunol CVI.* 2009;16:830–4.
35. Nielsen J, Ladekjær-Mikkelsen AS, Bille-Hansen V, Lohse L, Bøtner A. PCV2-associated disease following intrauterine infection (abstr). In: Proceedings of the International Pig Veterinary Society Congress. Hamburg, Germany; 2004. p. 14.
36. Mikami O, Nakajima H, Kawashima K, Yoshii M, Nakajima Y. Nonsuppurative myocarditis caused by porcine circovirus type 2 in a weak-born piglet. *J Vet Med Sci.* 2005;67:735–8.
37. Njaa BL. Porcine circovirus type 2 (PCV2). In: Kirkbride's diagnosis of abortion and neonatal loss in animals. 4th ed. West Sussex, UK: John Wiley & Sons, Ltd.; 2012. p. 100–3.
38. LeFebvre R. Fetal mummification in the major domestic species: current perspectives on causes and management. *Vet Med Res Rep.* 2015;233.
39. Janke BH. Case report: porcine circovirus as a cause of reproductive problems (abstr). In: Proceedings of the 118th Annual Meeting of the Iowa Veterinary Medical Association. Iowa, USA; 2000. p. 101.

Submit your next manuscript to BioMed Central and we will help you at every step:

- We accept pre-submission inquiries
- Our selector tool helps you to find the most relevant journal
- We provide round the clock customer support
- Convenient online submission
- Thorough peer review
- Inclusion in PubMed and all major indexing services
- Maximum visibility for your research

Submit your manuscript at
www.biomedcentral.com/submit

